

# Elvis: in the Mirror and the Medicine Cabinet

Elvis Presley, the legendary musician and cultural icon, had a range of health issues, some of which were exacerbated by his lifestyle, including his use of prescription medications. Here's a detailed overview of his medical conditions, surgeries, and medications:

## Medical conditions

1. **Hypertension:** Elvis suffered from high blood pressure, which was partially managed with medication.
2. **Glaucoma:** He had glaucoma, which affected his vision and required treatment.
3. **Bowel issues:** Elvis had chronic constipation, which is believed to have been aggravated by his use of opioids and poor diet. His autopsy revealed significant megacolon, which can result from chronic constipation.
4. **Drug dependence:** Elvis was dependent on a variety of prescription medications, including opioids, sedatives, and stimulants. This dependence began in the 1960s and continued until his death.
5. **Liver damage:** His autopsy showed signs of mild liver damage, likely due to his use of prescription drugs.
6. **Diabetes:** Elvis was diagnosed with Type 2 diabetes.
7. **Obesity:** By the time of his death, Elvis was overweight, which exacerbated many of his other health issues.
8. **Insomnia:** Elvis suffered from severe insomnia, which led to his use of a variety of sedatives.

## Surgeries

1. **Tonsillectomy:** As a child, Elvis had his tonsils removed. (**Location:** Unknown, but likely performed in a local hospital in Tupelo, Mississippi, during his childhood.)
2. **Nose surgery:** Elvis had surgery on his nose in 1957 to remove a nasal septum growth. This surgery was more for cosmetic reasons. (**Location:** A private clinic in Beverly Hills, California. This procedure was relatively minor and focused on removing a nasal septum growth.)
3. **Eye surgery:** He had surgery for his glaucoma in the 1970s. (**Location:** Memphis, Tennessee. Elvis was treated for glaucoma at Baptist Memorial Hospital in Memphis, which was a frequent location for his medical care.)

4. **Back surgery:** Elvis suffered from back pain and had back surgery in 1973 to alleviate chronic pain, possibly linked to his weight and physical exertion on stage. (**Location:** Baptist Memorial Hospital in Memphis, Tennessee. This hospital was one of the primary medical facilities Elvis used for his medical treatments and surgeries.)
5. **Dental procedures:** He had several dental surgeries, including caps and crowns, which were common for someone in the public eye. (**Location:** These were generally performed at private dental offices in Memphis, Tennessee, and Beverly Hills, California.)

## Hospitalisations

I	October 15 – November 1, 1973 Diagnoses: 1. Edema secondary to cortisone injection 2. Gastric ulcer 3. Hypertension 4. Toxic hepatitis 5. Headache secondary to post-concussion syndrome
II	January 28 – February 13, 1975 Diagnoses: 1. Sigmoid volvulus 2. Megacolon 3. Hypertension 4. Fatty infiltrates of liver
III	August 21 – September 1, 1975 Diagnoses: 1. Fatty liver 2. High cholesterol 3. Hypertension 4. Chronic obstructive pulmonary disease 5. Megacolon from laxative abuse
IV	April 1-5, 1977 <sup>b</sup> Diagnoses: 1. Gastroenteritis 2. Lumbosacral strain 3. Mild anemia

## Traumatic Brain Injury

“The most underappreciated factor in the decline of Elvis Presley's health and early death was repeated head trauma. It is now recognized that multiple head trauma can cause an autoimmune inflammatory disorder that can attack any organ in the body. Contemporary terms for the pathologic developments that may occur following head trauma are post-concussion syndrome, TBI, and chronic traumatic encephalopathy. Some of the post-trauma symptoms include memory loss, obsessive-compulsive traits, and irrational or illogical behavior. Elvis demonstrated many of these obsessive-compulsive and erratic behaviors at different times.”

<b>Date/Place</b>	<b>Event</b>
1956	Fight at a Memphis gas station
1956	Slugged by a man in Toledo
1958	Knocked down in a roller skating contest
1967	Tripped over a television cord and hit his head on the bathtub. Unconscious for indeterminable amount of time.

<sup>a</sup>In addition, Elvis Presley had periods in his life in which he participated in martial arts, football, and horse and motorcycle riding. He also had at least four major drug overdoses, which required resuscitation.

“After his TBIs, Elvis' behavior became progressively erratic and irrational. For example, it is reported that in 1975 he refused to bathe and developed sores on his body. He ordered unknown pills from Sweden, which supposedly would cleanse him from within. During his 2 weeks of hospitalization in August-September 1975, he complained of 26 headaches, 14 bouts of insomnia, and "general pain, hurting all over" 4 or 5 times each nursing shift. The triad of insomnia, headaches, and pain all over is typical of TBI victims.”

[Source: <https://www.medcentral.com/pain/chronic/elvis-presley-head-trauma-autoimmunity-pain-early-death>]

## Cosmetic treatments

### 1. Facial procedures

There have been rumours that Elvis had minor cosmetic procedures, such as a chin implant or eyelid surgery (blepharoplasty). However, these rumours are not confirmed with solid evidence. If he had such procedures, they would have been subtle and aimed at maintaining his appearance as he aged.

### 2. Dermabrasion


Elvis is reported to have undergone dermabrasion, a skin-resurfacing procedure, to treat scars from acne, which he had struggled with as a young adult. This procedure would have been done to smooth out the skin and improve its texture.

While there's no extensive documentation of Elvis undergoing major plastic surgery or skin treatments, the combination of minor cosmetic procedures, careful grooming, and skincare likely contributed to his well-maintained appearance throughout his career.

## Before



## After



## Medications

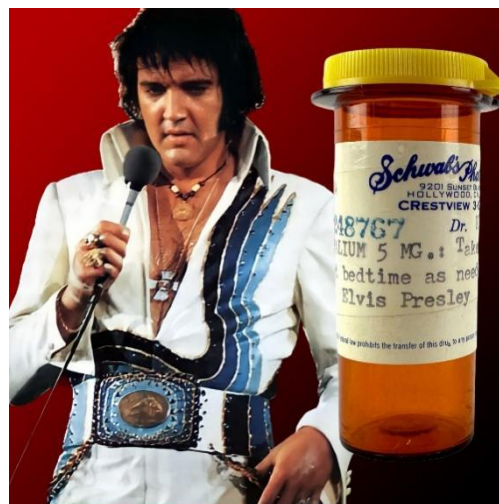Elvis was prescribed a wide range of medications, often in large quantities, by his personal physician, Dr George Nichopoulos, also known as "Dr Nick". Here are some of the medications he used:

### 1. Sedatives:

- **Diazepam (Valium):** Used to treat anxiety and muscle spasms.
- **Placidyl (Ethchlorvynol):** A sedative used to treat insomnia.
- **Methaqualone (Quaaludes):** A sedative-hypnotic medication for insomnia.

2. **Stimulants:**
  - **Amphetamines:** Elvis used various amphetamines, such as Dexedrine, to stay awake and maintain his energy levels for performances.
3. **Painkillers:**
  - **Dilaudid (Hydromorphone):** A potent opioid pain medication.
  - **Codeine:** Another opioid used for pain relief.
4. **Antihistamines:**
  - **Antihistamines:** Elvis took these to manage his allergies.
5. **Antidepressants:**
  - **Amitriptyline:** An antidepressant that is also used for pain management.
6. **Antihypertensives:**
  - **Propranolol:** A beta-blocker used to manage high blood pressure and anxiety.
7. **Other Medications:**
  - **Lasix (Furosemide):** A diuretic used to manage fluid retention and hypertension.
  - **Corticosteroids:** Used to manage his various inflammations and conditions like glaucoma.

Elvis's death in 1977 was attributed to a heart attack, but his health problems were compounded by his prolonged and heavy use of prescription medications. His death was initially recorded as cardiac arrhythmia, but later studies and testimonies suggested that his drug use played a significant role.



# Elvis Presley: Head Trauma, Autoimmunity, Pain, and Early Death

Part of [Volume 13, Issue 5](#)

## CITE THIS ARTICLE

Tennant F. Elvis Presley: Head Trauma, Autoimmunity, Pain, and Early Death. *Pract Pain Manag.* 2013;13(5).

Updated Jun 14, 2017

🕒 22 Min Read

Forest Tennant, MD, DrPH, Head, Arachnoiditis Research and Education Project

## Controversy Over Cause of Death

“When Elvis Presley "unexpectedly" died on August 16, 1977, a great public controversy erupted. The pathologists—including the coroner of Shelby County, Tennessee—found that Elvis died of a heart attack. However, ABC's "20/20," anchored by Ted Koppel, believed Elvis had died of a drug overdose and stated there was a cover-up regarding his death. They questioned why criminal charges had not been filed against Dr. Nick by the Shelby County district attorney. The popularity and influence of this show had an impact. The Tennessee medical board investigated the matter and acquitted Dr. Nick of acting unethically, unprofessionally, or of gross malpractice, but they convicted him of improperly prescribing medications to 10 individual patients, including Elvis Presley and the singer Jerry Lee Lewis. Shortly thereafter, the district attorney general's office brought a criminal indictment against Dr. Nick alleging that he had willfully and feloniously prescribed controlled substances to the same 10 individuals for which the board found him guilty.”

## Autopsy Report

“Elvis Presley's autopsy was the root cause of the public controversy. As many have read, Elvis was found dead, face down, on the bathroom floor by his live-in girlfriend, Ginger Alden. How long he had been dead is unknown, but attempts to revive him were unsuccessful. His autopsy was performed at Baptist Memorial Hospital in Memphis on the day he died. The head pathologist was Thomas McChesney, MD; the consultant to the case was Jerry T. Francisco, MD, county coroner of Shelby County. The final pathological diagnoses are listed in Table 1.

One major finding was the severity of Elvis Presley's heart and cardiovascular disease. Although he was under treatment for hypertension, Dr. Nick—as well as the other doctors who saw Elvis when he was hospitalized—were not aware that his heart was about double the normal size (520 g) and that he had significant atherosclerosis in his coronary vessels, aorta, and cerebral arteries.

It was also discovered that he had an antitrypsin deficiency, which is a rare genetic condition that causes emphysema. Microscopic examination of his lungs revealed "a rare interstitial lymphoid, inflammatory infiltrate, particularly beneath the epithelium of bronchi."<sup>4</sup> The diagnoses listed in the table are verbatim from Elvis' autopsy report. Interestingly, the pathologists tested him for immune deficiencies, and found Elvis had hypogammaglobulinemia, a disorder of the body's immune system, as indicated by decreased levels of immunoglobulin A (IgA) and IgG. Rosette formation studies revealed decreased numbers of T cells and B cells (lymphocytes).

My retrospective review of his autopsy findings, when paired with his medical history of multi-organ abnormalities over a 10-year period, clearly reveals that Elvis was suffering from an autoimmune inflammatory disorder.”

1	Cardiomegaly with left ventricular hypertrophy
2	Coronary atherosclerosis, mild to moderate
3	Pulmonary edema, mild to moderate
4	Pulmonary aspiration, mild
5	Hepatomegaly due mainly to fatty metamorphosis of liver
6	Splenomegaly, mild, mainly congestive
7	Arteriosclerosis of kidneys, moderate
8	Nephrosclerosis, mild
9	Papillary necrosis, ancient, single papilla, left
10	Atherosclerosis of aorta and cerebral arteries, mild
11	Livor mortis, pronounced, upper half of body
12	Capillary congestion and petechial, skin, upper half of body
13	Chemosis, bilateral, moderate
14	Cardiac puncture wounds, recent
15	Gastric hemorrhage, recent, mild
16	"Soldier's patch," pericardium
17	Scar, left inferior eyelid
18	Scar, dorsum, right hand
19	Scar, left buttock
20	Clinical: antitrypsin deficiency (genotype MS)

[Source: <https://www.medcentral.com/pain/chronic/elvis-presley-head-trauma-autoimmunity-pain-early-death>]

OFFICE OF THE COUNTY MEDICAL EXAMINER  
858 Madison Avenue  
MEMPHIS, TENNESSEE 38103

Case No. 77-1944

**REPORT OF INVESTIGATION BY COUNTY MEDICAL EXAMINER**

DECEASED: Elvis Presley RACE: W SEX: M AGE: 42  
 HOME ADDRESS: 3764 Elmwood Dr. Memphis, Tenn. M W S D OCCUPATION: Artist  
 TYPE OF DEATH:  Violent  Casualty  Suicide  Sudden when in apparent health  Found Dead   
 In Prison  Suspicious, unusual or unnatural  Cremation

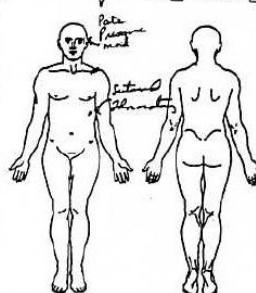
II Motor Vehicle Accident Check One:  Driver  Passenger  Pedestrian  Unknown

Notification by: City of Memphis Address: City  
 Investigating Agency: SCM # 1-1700

Married or never:  Married  Unmarried  Partly Married  Circumcised Yes  No

Eyes: Blue Hair: Black Mustache: 0 Beard: 0  
 Weight: 165 Height: 5'11" Body Temp: 98.6 Date and Time: 8-16-77  
 Rigor: Yes  No  Lymph:  Liver Color: Normal Fixed  Non-Fixed

Mark and Wounds:  
Contusion to forehead  
Hand at B.M.H.



PROBABLE CAUSE OF DEATH: HCDI associated with ASA

MANNER OF DEATH:  (Check one only) Accident  Natural  Suicide  Unknown  Homicide  Pending  Pathologist

DISPOSITION OF CASE:  1. Not a medical examiner case  2. Autopsy requested Yes  No  Autopsy ordered Yes  No  Pathologist

I hereby declare that after receiving notice of the death described herein I took charge of the body and made inquiries regarding the cause of death in accordance with Section 10-70-2(a), Tennessee Code Annotated; and that the information contained herein regarding such death is true and correct to the best of my knowledge and belief.

8/16/77 Signature of County Medical Examiner

Revised 2-1-67  
CME-1

PERSONAL HISTORY: Suicide attempt  Suicide threat  Hobbs, attitude and skills with firearms, chemicals, etc. Domestic, premarital or marital conflicts  Financial or business reverse  Social or religious conflicts  Legal difficulties  Criminal record  Unemployment  Fear of disease  Other (specify):

CONDUCT BEFORE DEATH: Efforts to prevent help  Efforts to obtain help  Suicide attempt: Admitted  Denied  Refusal to talk  Written declaration of intended suicide  Accusations against others  Other (specify):

LAST SEEN ALIVE	INJURY OR ILLNESS	DEATH	SURVEY	MEDICAL EXAMINER ADVISED	VIEW OF BODY	POLICE NOTIFIED
8-16-77		8-16-77	8-16-77	8-16-77	8-16-77	8-16-77
08:00		15:30	14:00	16:00	17:30	15:30

INJURY OR DISEASE OF ILLNESS: None  
 DEATH: None  
 VIEWING OF BODY BY MEDICAL EXAMINER: Dr. B.M.H. - Room attempted  
B.M.H.

MEDICAL ATTENTION AND HOSPITAL OR INSTITUTIONAL CARE

NAME OF PHYSICIAN OR INSTITUTION	ADDRESS	CITY/STATE	DATE
<u>A. Nichopoulos</u>	<u>Memphis</u>	<u>Memphis/Tenn.</u>	

CIRCUMSTANCES OF DEATH

NAME	ADDRESS
<u>Therese Alden</u>	<u>Same</u>
<u>None</u>	

NARRATIVE SUMMARY OF CIRCUMSTANCES SURROUNDING DEATH:  
 Found on floor of dressing room by door who had been sleeping in adjoining room. No indication of foul play. Had been ok in early am. Hgt of playing basketball in early am. Family court signed for autopsy - to be performed at B.M.H.

[Source: <https://elvisondvcd.de/autopsy.html>]

**GEORGE NICHOPOLOUS, M.D.**  
 1734 MADISON AVENUE  
 MEMPHIS, TENNESSEE 38108  
 PHONE 726-0200 OR 345-4478

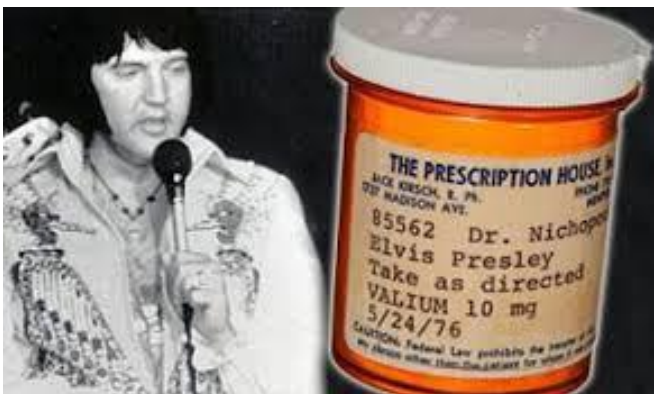NAME: Elvis A. Presley DATE: Aug 15 '77  
 ADDRESS: Graceland, Memphis

Rx

Dilaudid - 50 - 4 mg. tab  
 " - 20 cc - 2 mg sol.

Quaalude 150 - 300 mg. tab  
 Dexedrine 100 - 5 mg tab  
 Percodan 100 tabs.  
 Amytal - 100-3 gram caps  
 - 12 half gram amps.  
 Bipheta mine-100, 20 mg. spansules

George Nichopolous MD MD REP \_\_\_\_\_ TIMES  
 Rx No. 23137 A030785 NE REP \_\_\_\_\_



[Source: <https://www.thegearpage.net/board/index.php?threads/elvis-2-months-before-passing.2051599/page-8>]